

Cervical Cancer

WWW.RN.ORG®

Reviewed January 2024, Expires January 2026

Provider Information and Specifics available on our Website

Unauthorized Distribution Prohibited

©2024 RN.ORG®, S.A., RN.ORG®, LLC

By Wanda Lockwood, RN, BA, MA

Purpose

The purpose of this course is to describe the development of cervical cancer, risk factors, causes, diagnostic procedures, symptoms, and treatment options.

Goals

Upon completion of this course, the healthcare provider should be able to:

- List at least 6 risk factors for development of cervical cancer. Describe cervical intraepithelial neoplasia.
- Describe the impact human papillomaviruses have on cervical cancer.
- Describe at least 4 symptoms of cervical cancer.
- Describe the differences in appearance among the normal cervix, cervical polyps, and cervical dysplasia.
- Describe and interpret results of a Pap smear.
- Discuss the use of HPV DNA testing.
- Describe 2 types of biopsy procedures.
- Describe the appearance of the cervix with low-grade, high-grade, and invasive cancer.
- Describe cervical cancer staging, 0-IV.
- Describe treatment options for different cervical cancer stages.
- Describe 5 different surgical approaches.
- Describe 2 vaccine choices.

Introduction

Cervical cancer should be a rare disease. It has a precursor—cervical intraepithelial neoplasia (CIN)—that is easily treated in the early stages. It progresses slowly from stage 1 to stage 4, and it can be identified with a simple test, the Pap smear. Nevertheless, despite progress that has reduced incidence in the United States by about a third over the last couple of decades, cervical cancer remains the

second most common cancer in women (after breast cancer) worldwide. About 90% of cervical cancer is squamous cell carcinoma with the remaining 10% adenocarcinoma or mixed adenosquamous carcinoma. Most cases of cervical cancer, squamous cell carcinoma and adenocarcinoma, are directly linked to human papillomavirus infection (primarily types 16 and 18). **[See CE course: Human Papillomavirus (HPV): Genital Warts and Recurrent Respiratory Papillomatosis (RRP).]** In 2010, about 12,000 women in the United States were diagnosed with cervical cancer, resulting in approximately 4000 deaths. An additional 50,000 women developed carcinoma *in situ*. Incidence is highest in those 30 to 45, but cervical cancer may occur much earlier in some individuals.

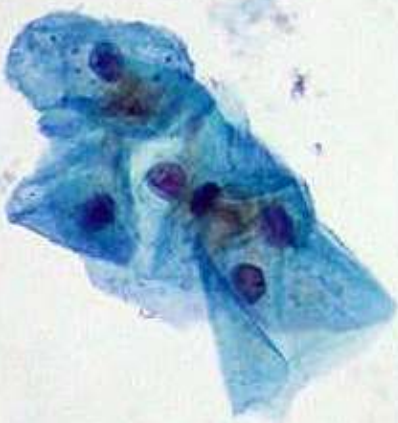

Risk factors

- Early intercourse (<20)
- Early childbearing
- Multiple sex partners
- History of STDs
- Multipara (3-5 children)
- High-risk partner (male with female partner who has had cervical cancer, uncircumcised male)
- History of human papillomavirus (HPV) infection
- Smoking or exposure to second-hand smoke
- High parity
- Intrauterine DES exposure
- Use of oral contraceptives ≥ 5 years
- Low socioeconomic status
- Chronic cervical infections
- Immunosuppression (HIV/AIDS, therapy)
- Nutritional deficiencies (folate, beta-carotene, and vitamin C)
- Obesity

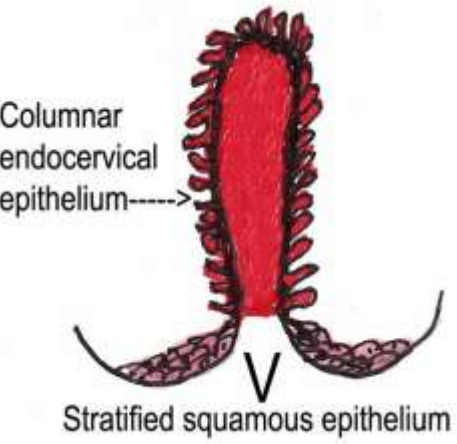
How is cervical cancer diagnosed?

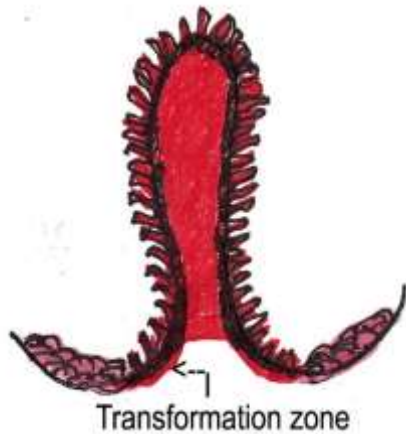Cervical intraepithelial neoplasia (CIN) is also referred to as cervical dysplasia (appearance of abnormal cells) and is a precursor to cervical cancer. Cervical dysplasia is most commonly caused by infection with human papillomavirus (HPV). About 40 different types of HPV can be transmitted through sexual activity. Those of primary concern include HPV 6 and 11, which cause condylomata acuminata (genital warts). Almost all cervical cancers are related to infection with high-risk HPV. Approximately 15 types of HPV are considered high risk for cancer, especially HPV 16 and 18, which are implicated in about 70% of cervical cancer cases.

Up to 80% of women who are sexually active develop an HPV infection at some time, but many are asymptomatic, and the infection often clear spontaneously within 2 years. However, some people develop persistent infections of high-risk HPV. As HPV invades the cells, it causes abnormal cell changes that are precursors to cancer. Most women treated for CIN are young, often in their 20s while those diagnosed with cervical cancer tend to be older because of the slow progression of the disease.

Normal cells	HPV-invaded cells
	

The transformation zone of the cervix is especially vulnerable to dysplasia and development of cancer.

 <p>Columnar endocervical epithelium-----></p> <p>Stratified squamous epithelium</p>	<p>Before puberty, the exposed external cervix is lined with flat stratified squamous epithelium while the interior of the cervix is lined with columnar endocervical epithelium. Before puberty, the junction where the squamous epithelium meets the columnar epithelium (squamocolumnar junction—SCJ) is right above the cervical os.</p>
	<p>During puberty, the cervix begins to mature with the squamocolumnar junction (SCJ) rolling outward along with some of the columnar endocervical</p>



endothelium. The newly exposed columnar endothelium comes in contact with vaginal secretions and increased hormones. Over time, the exposed columnar endothelium begins to be replaced by squamous epithelium (squamous metaplasia) and a new SCJ forms. This area that is between the old junction and the new—the transformation zone—is vulnerable and is where most cancers of the cervix occur. During menopause, the process is reversed with the SJC pulled back toward the interior of the uterus again so part of the transformation zone may not be visible.

There is no treatment for HPV infection, but the dysplasia or lesions (such as cervical warts) can be treated. Common treatments for dysplasia include cryosurgery, loop electrosurgical excision procedure (LEEP), and conization. Abnormal cells are removed, and healthy tissue regenerates.

Symptoms



Cervical cancer is often advanced before symptoms occur, and symptoms may be somewhat non-specific. Signs and symptoms include:

- Vaginal bleeding.
- Unusual vaginal discharge.
- Pain during sexual intercourse.
- Post-coital bleeding (often an initial symptom).
- Pelvic pressure or pain.

As the tumor grows, it tends to spread superiorly into the endometrial cavity, inferiorly to the vagina, and laterally to the pelvic wall. The tumor may also spread directly to the bladder and rectum, resulting in associated symptoms, such as hematuria, fistulae, ureteral obstruction with hydronephrosis. Pelvic wall involvement is characterized by a triad of symptoms: leg edema, pain, and hydronephrosis.

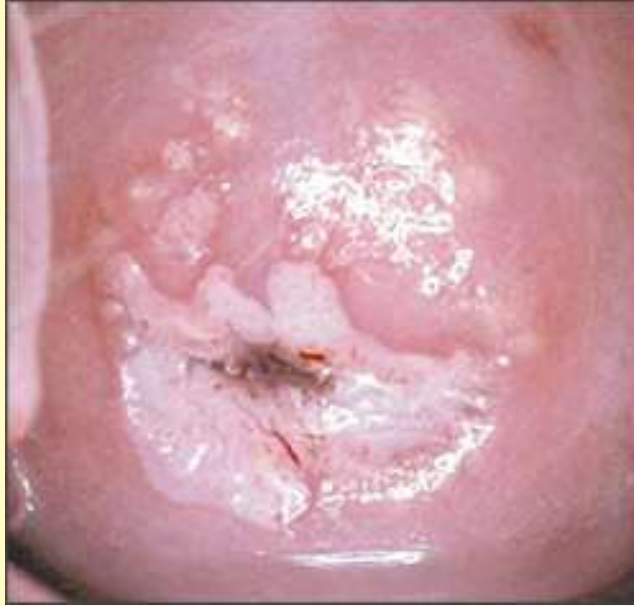Pelvic exam, non-cancerous findings

The pelvic examination is essential for diagnosis and involves visual inspection of the cervix and surrounding tissue. A normal cervix should be smooth with no obvious abnormalities. A variety of different lesions may be noted, including polyps or genital warts. Dysplasia generally arises from the transformation zone (about 95%) with changes noted about the cervical os.

Non-cancerous findings	
Normal cervix	 A close-up photograph of a normal cervix. The cervix is smooth, pinkish-red, and has a central opening (cervical os) that is slightly recessed. The surrounding vaginal tissue is also visible, appearing moist and pink.
Cervical polyp	 A close-up photograph of a cervical polyp. The polyp is a fleshy, reddish, lobulated mass protruding from the cervical os. The surrounding vaginal tissue is visible, appearing moist and pink.

Cervical dysplasia

(Note acetic acid solution makes abnormal areas appear pearly or white).



Pap smear

The most common test to determine the presence of CIN or cancer is the Pap smear. Each year about 50 million women in the United States have a Pap smear, and approximately 7% have abnormal results. During a Pap smear, cells are scraped from both the exocervix and endocervix. Abnormal cells are described and graded with the terms "squamous epithelial lesion" and "atypical squamous cells."

- Low-grade squamous epithelial lesion: LSIL.
- High-grade squamous epithelial lesion: HSIL.
- Possible cancer: Malignant.
- Atypical squamous cells, undetermined significance: ASC-US.
- Atypical squamous cells, cannot exclude HSIL: ASC-H.

HPV DNA testing

HPV is classified as low-risk if it usually does not cause cancer and high risk if it does. HPV types 6 and 11 are associated with condylomata acuminata (genital warts) and have a low risk of cancer; however, most cases of cervical cancer are directly related to infection with HPV types 16 or 18, which pose a high risk of cancer. Therefore, based on the results of the Pap smear, HPV DNA testing may be indicated. For example, if the Pap smear shows ACS-US, this correlates with a 3% to 10% chance of a higher-grade lesion being present, but if the HPV DNA test is negative for HPV, then the risk of cancer lessens, so this person may have follow-up in one year rather than more frequent follow-up or colposcopy, which would be indicated if the HPV DNA test were positive for types 16 or 18.

While genital warts is caused by low-risk HPV, women are often co-infected with more than one type of HPV, so women with genital warts cannot assume they are at low risk for cancer but should consider HPV DNA testing as well.

Biopsy

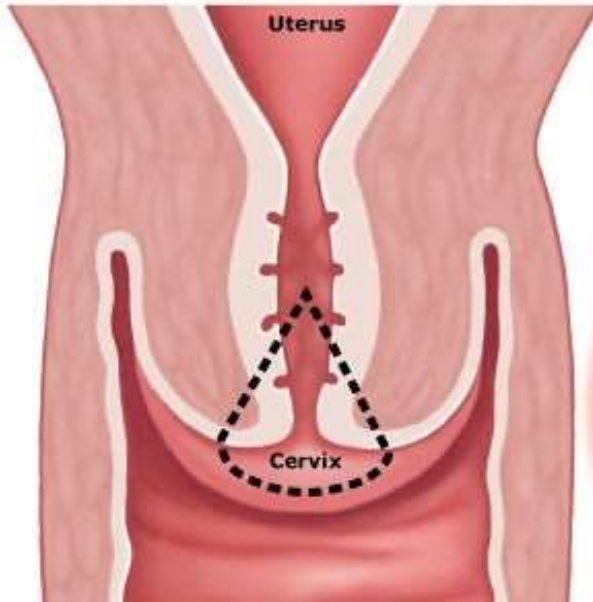
If abnormalities are observed in the Pap smear report or pelvic examination, a biopsy may be performed. **Colposcopy with direct biopsy** is recommended with Pap smears with LSIL. A colposcopy uses a binocular stereomicroscope with a light source with green filters to help identify abnormal blood vessels. Applying 3% to 5% acetic acid solution for 5 to 10 minutes prior to colposcopy helps to make lesions more visible so they can be more easily detected. A punch biopsy in which a small amount of surface tissue is removed is the usual procedure. Sometimes multiple biopsies may be taken.

In order for a colposcopy to be considered satisfactory, the healthcare provider must be able to visualize the entire squamocolumnar junction (SJC). If part is not visible, then other methods must be employed, such as cone biopsy/loop electrical excision. Pap smears graded HSIL or malignant may require colposcopy, biopsy or conization, endocervical sampling and sometimes endometrial sampling to determine whether the cancer is high-grade preinvasive or invasive.

The biopsy report uses the term "cervical intraepithelial neoplasia" to grade dysplasia.

- CIN I: Mild dysplasia.
- CIN II: Moderate to marked dysplasia.
- CIN III: Severe dysplasia to carcinoma *in situ*.

If initial Pap and biopsy findings indicate CIN III or HSIL, a cone biopsy is done. The **cone biopsy/conization** is more extensive and takes a cone-shaped wedge of tissue, including all abnormal cells if possible. The sample usually encompasses the complete transformation zone and extends up into the endocervical canal. In some cases, conization may be used to treat dysplasia or carcinoma *in situ*.



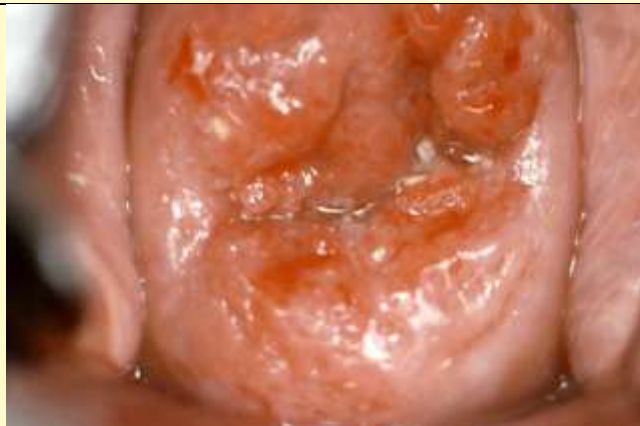During the cone biopsy, tissue is excised by various means: cold knife, laser, large loop excision of the transformation zone (LLETZ) or loop electrosurgical excision procedure (LEEP). The cone biopsy may be done under general, regional, or local anesthesia. Excessive bleeding may occur 5 to 10 days after the procedure, so the patient must be cautioned to report signs of bleeding. Over time, the tissue fills in and heals, but some people may develop cervical stenosis or incompetence.

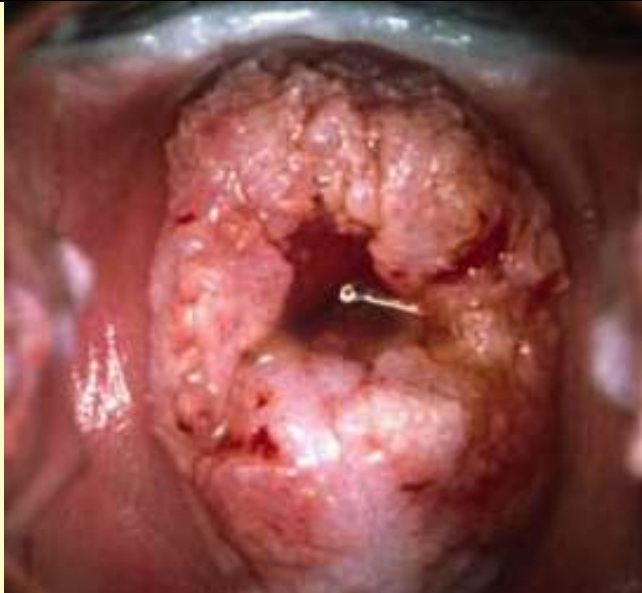

Pelvic exam, cancerous findings

If malignant cells on the surface of the cervix began to multiply, eventually they invade deeper tissues and may enter blood vessels and lymph vessels and spread to adjacent and then distant tissues.

Cancerous findings

Low-grade cervical cancer



<p>High-grade cervical cancer</p>		
<p>Invasive cervical cancer</p>		

If cancer is found, yet another grading system is used to describe the extent of spread. Stages I and II are low-grade cancers and stages III and IV are high-grade cancers.

Stages	Descriptions of cancer
0	Carcinoma <i>in situ</i> .
I	Confined to cervix. <ul style="list-style-type: none"> • IA Preclinical. • IA1 Microscopically-evident stromal invasion, minimal. • IA2 Microscopic lesions ≤5 mm deep with horizontal spread ≤7 mm. • IB All other cases confined to cervix.
II	Extends beyond cervix but not to pelvic wall. Involves

	proximal vagina (excluding the distal third). <ul style="list-style-type: none"> • IIA: No obvious parametrial involvement. • IIB: Obvious parametrial involvement.
III	Extends to pelvic wall. Rectal exam show no cancer-free area between tumor and pelvic wall. Cancer involves distal third of vagina and may involve kidney (evidenced by non-functioning or hydronephrosis). <ul style="list-style-type: none"> • IIIA: Does not extend to pelvic wall but involves distal third of vagina. • IIIB: Extends to pelvic wall and involves kidney (hydronephrosis, non-functioning).
IV	Extends beyond pelvis or involves mucosa of bladder or rectum. <ul style="list-style-type: none"> • IVA: Has spread to adjacent pelvic organs. • IVB: Has spread to distant organs.

Additional tests

If cancer is diagnosed, a variety of other tests may be done to determine the spread of the cancer, especially with advanced cancers. Tests may include:

- Cystoscopy to examine the bladder.
- Colonoscopy or proctoscopy to examine the large intestine and rectum.
- Imaging studies: CTs, chest-x-ray, MRIs, and PET scans.

When metastasis occurs, the most common sites are extrapelvic lymph nodes, liver, lung, and bone, so other tests (such as liver function tests) may be indicated depending on sites where metastasis has occurred.

Treatment

Treatment varies depending upon the stage of the cancer, depth of invasion, age, desire to retain reproductive ability, prognosis, condition, and patient preference.

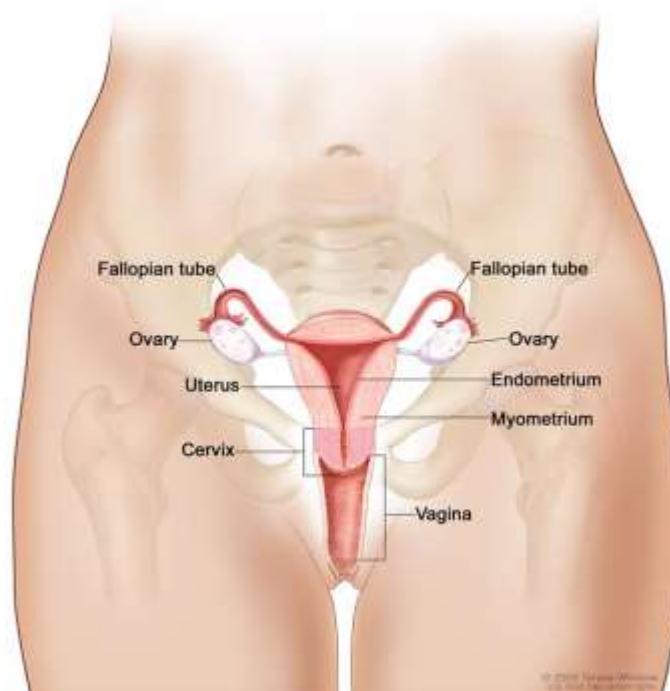
Stage	Treatment
0	Options include: <ul style="list-style-type: none"> • Conization (cold knife or LEEP). • Cryosurgery. • Laser surgery. • Total hysterectomy (post-reproductive). • Internal radiation therapy.
IA1	Conization (in some cases) or simple hysterectomy (most common).

IA2	Options include: <ul style="list-style-type: none"> • Modified radical hysterectomy with lymphadenectomy. • Total hysterectomy. • External beam pelvic radiation (and ≥ 2 intracavitary brachytherapy applications). • Radical vaginal trachelectomy. • Intracavitary radiation.
IB1	Options include: <ul style="list-style-type: none"> • Radical hysterectomy with lymphadenectomy followed by total pelvic radiation and chemotherapy. • External beam pelvic radiation and ≥ 2 intracavitary brachytherapy applications. • Radiation and chemotherapy with cisplatin or cisplatin/5-FU. • Radical vaginal trachelectomy.
IB2	Options include: <ul style="list-style-type: none"> • Primary chemotherapy and radiotherapy. • Radical hysterectomy with lymphadenectomy and chemotherapy and radiotherapy.
II	Options include: <ul style="list-style-type: none"> • Primary chemotherapy and radiotherapy. • Radical hysterectomy with lymphadenectomy and chemotherapy and radiotherapy.
IIA and IIB	Options include: <ul style="list-style-type: none"> • External beam pelvic radiation combined with intracavitary radiation plus chemotherapy with cisplatin or cisplatin/5-FU or gemcitabine. • Radical hysterectomy and lymphadenectomy. • Radical hysterectomy and lymphadenectomy with postoperative total pelvic radiation therapy plus chemotherapy.
III	Radiation therapy plus chemotherapy: Intracavitary radiation and EBRT to the pelvis combined with cisplatin or cisplatin/5-FU or gemcitabine.
IVA	Radiation therapy plus chemotherapy: Intracavitary radiation therapy and external-beam pelvic radiation therapy combined with cisplatin or cisplatin/5-FU or gemcitabine.
IVB	Radiation may be used for palliative treatment. No chemotherapy has proven effective but a number of clinical trials are in progress.

Most women treated for cervical cancer have surgery in addition to radiation therapy and chemotherapy. There are often few options for

women with recurrent cervical cancer who have already undergone surgery, radiation, and chemotherapy. Survival rates at 5 years range from 5 to 15%. Pelvic exenteration has been used in some of these cases. Others may choose to participate in clinical trials.

Procedures



National Cancer Institute

Simple/Total hysterectomy	The cervix and uterus are removed, but the vagina, ovaries, and other structure are left intact.
Radical hysterectomy and lymphadenectomy	The cervix, uterus, proximal vagina, ovaries and fallopian tubes are removed as well as tissue around the cervix and pelvic lymph glands.
Modified radical hysterectomy	The cervix, uterus, and proximal vagina are removed.
Radical vaginal trachelectomy (RVT)	Most, if not all, of the cervix, its contiguous parametrium, and vaginal cuff, are removed and a laparoscopic pelvic lymphadenectomy is done. The uterus is left intact so that the person can conceive and carry a pregnancy. This procedure is recommended for those ≤ 40 who wish to retain fertility and bear children.
Pelvic	This radical procedure removes all organs from

exenteration	the abdominal cavity (usually following a radical hysterectomy), including removal of the bladder, urethra, rectum, anus, vagina, and vulva. Permanent colostomy and vesicostomy are created.
---------------------	---

Sadly, almost half of cervical cancers are still diagnosed at advanced stages. According to the CDC:

Screening for cervical cancer with the Pap test should begin for women within three years of beginning sexual activity or at age 21 (whichever comes first). Furthermore, women should be screened annually with three consecutive normal Pap tests and then at least every three years up to age 64 years.

The overall 5-year survival rate for cervical cancer has improved to 75% in the United States, but the rate varies according to the grade of the cancer.

Stage	5-Year Survival Rate
0	93%
IA	93%
IB	80%
IIA	63%
IIB	58%
IIIA	35%
IIIB	32%
IVA	16%
IVB	15%

Two vaccines have been developed to prevent HPV infection and are now recommended for all girls, ages ≥ 9 -26 (usually given at ages 11-12 before sexual activity). Vaccination is now also recommended for boys/men as well. These vaccines are not effective against all high-risk HPV, but drug companies are working to develop new vaccines to target more high-risk HPVs.

HPV vaccines	
Gardasil®	Gardasil® is indicated for prevention of HPV types 6, 11, 16, and 18, so it is effective for prevention of both cancer (cervical, vulvar, vaginal, and anal) and genital warts. This vaccine is administered in 3 separate doses: initial, 2 months later, and 6 months later.
Cervarix®	Cervarix® is indicated for prevention of HPV types 16 and 18, so it is not effective for prevention of genital

	warts. This vaccine is administered in 3 separate doses: initial, 2 months later, and 6 months later.
--	---

Summary

Most cases of cervical cancer are caused by sexual transmission of human papillomavirus (HPV), especially types 16 and 18, which cause cervical intraepithelial neoplasia (CIN), also called cervical dysplasia, a precursor to cervical cancer. The transformation zone of the cervix is the most vulnerable to dysplasia and the initial site of most cervical cancers. Cervical cancer may be asymptomatic until it is advanced. The initial symptom is often post-coital bleeding, but some may experience vaginal bleeding, vaginal discharge, painful intercourse, and/or pelvic pressure or pain. The pelvic exam and Pap smear are critical for diagnosis of CIN and cervical cancer. If dysplasia is found, HPV DNA testing may be done to determine the type of HPV and the risk of cancer. In some cases colposcopy and direct biopsy or cone biopsy may be indicated. Cervical cancer is graded 0 (carcinoma *in situ*) to IV (metastatic). The most common treatment is hysterectomy followed by radiation and chemotherapy, but this may vary depending on the stage of the cancer, the person's age, and other variables. Two vaccines have been developed to prevent HPV infections: Gardasil® is effective against infection with HPV 6, 11, 16, and 18 while Cervarix® is effective against only HPV 16 and 18.

References

- Cancer advances in focus. (2010, November 29). *National Cancer Institute*. Retrieved February 3, 2020, from <http://www.cancer.gov/cancertopics/cancer-advances-in-focus/cervical>
- Cancers Diagnosed at Late-Stages Despite Available Screening Tests. (2010, November 24). *CDC*. Retrieved February 3, 2020, from <http://www.cdc.gov/media/pressrel/2010/r101124.html>
- Cervical cancer (Cancer of the cervix). (2008, November 20). *MedicineNet*. Retrieved February 3, 2020, from http://www.medicinenet.com/cervical_cancer/article.htm
- Cervical cancer. (2010, May). *CDC*. Retrieved February 3, 2020, from http://www.cdc.gov/cancer/cervical/pdf/Cervical_FS_0510.pdf
- Cervical cancer. (2020, January 5). *eMedicine*. Retrieved February 3, 2020, from <http://emedicine.medscape.com/article/253513-overview>
- Cervical cancer treatment (PDQ®). (2010, April 6). *National Cancer Institute*. Retrieved February 3, 2020, from

- <http://www.cancer.gov/cancertopics/pdq/treatment/cervical/patient/>
- Human papillomaviruses and cancer. (2010, December 13). *National Cancer Institute*. Retrieved February 3, 2020, from <http://www.cancer.gov/cancertopics/factsheet/Risk/HPV>
 - Loop electrosurgical excision procedure. (2020). *ACOG*. Retrieved February 3, 2020, from http://www.acog.org/publications/patient_education/bp110.cfm
 - Oral contraceptives and cancer risk: Questions and answers. (2006, May 4). *National Cancer Institute*. Retrieved February 3, 2020, from <http://www.cancer.gov/cancertopics/factsheet/Risk/oral-contraceptives>
 - Treatment Regimen Extends Survival for Women with Cervical Cancer. (2009, June 29). *National Cancer Institute*. Retrieved February 3, 2020, from http://www.cancer.gov/clinicaltrials/results/gemcitabine_cervical_0609
 - Tutorial of a robotic-assisted anterior pelvic exenteration [Video]. (2009, January 22). *ORLive*. Retrieved February 3, 2020, from <http://www.orlive.com/davinci/videos/tutorial-of-a-robotic-assisted-anterior-pelvic-exenteration?view=displayPageNLM>
 - What you need to know about cervical cancer. (2008, November 20). *National Cancer Institute*. Retrieved February 3, 2020, from <http://www.cancer.gov/cancertopics/wyntk/cervix>
 - Zeller, J.L. (2007, November 21). Carcinoma of the cervix. *JAMA* 298 (19). Retrieved February 3, 2020, from <http://jama.ama-assn.org/content/298/19/2336.full.pdf>